Identify the whole structure

Use the lumen, wall tissues and surrounding lung as a combination of clues. A single dark band, empty space or apparent diameter is not enough to identify an airway.

1. COMPARE FOUR PATTERNS

Trachea	A broad airway with a thick wall and C-shaped cartilage support. The posterior gap is bridged by trachealis muscle. A cropped section may show only part of the cartilage.
Bronchus	An airway within the lung with cartilage plates, a smooth-muscle layer and an epithelial lining. The mucosa may be folded. Nearby alveoli support an intrapulmonary location.
Bronchiole	An airway without cartilage or submucosal glands. Smooth muscle surrounds its lining; the lumen may look folded or star-shaped. Check the complete wall before claiming cartilage is absent.
Alveoli	Numerous irregular air spaces separated by delicate septa containing capillaries. This is a network of thin exchange walls, not one thick-walled conducting tube.

2. CHECK CONTEXT BEFORE SIZE

An oblique section can make a tube look oval and its wall uneven. Smooth-muscle contraction and preparation can alter the lumen shape. Use the scale bar, not the printed image size. A small field from an electron micrograph may identify a tissue layer without identifying the whole airway.

A blood vessel can lie beside a bronchiole. Look for blood cells, an endothelial lining and the absence of a ciliated airway lining; combine features rather than relying on whether the lumen looks empty.

Tracheal section: Histology Guide, MH 136.
Bronchiolar and alveolar sections: Histology Guide, MH 138.
Bronchial cartilage, muscle and surrounding alveoli: Digital Histology.

Scope: Cambridge Biology 9700 syllabus, section 9.1, outcome 4, p. 29.

Plan diagram: tracheal wall

A plan diagram records tissue boundaries and relative proportions, not individual cells. The example below is an idealised transverse section showing the major regions only.

1. SHOW REGIONS WITH CLEAN, UNFILLED OUTLINES

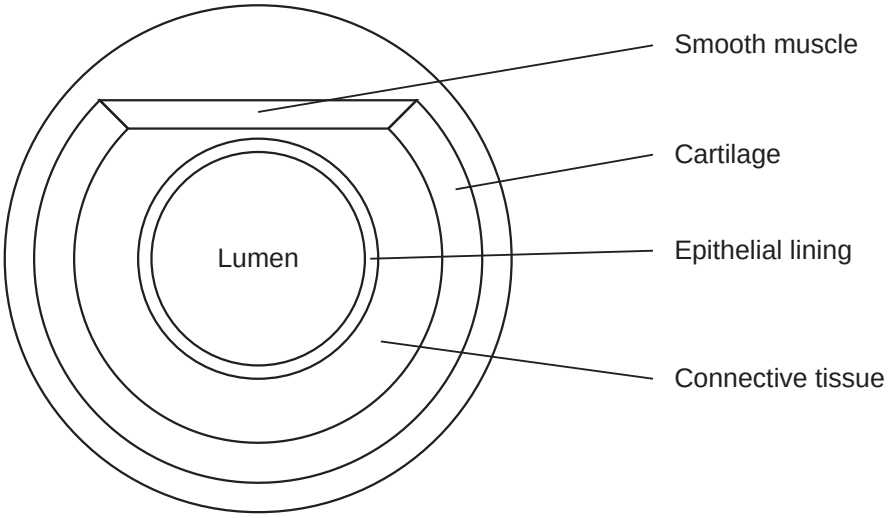

Posterior gap at top; connective tissue lies beneath the lining.
Teaching model only: not a traced specimen and not to scale.

2. RECORD WHAT THE SECTION ACTUALLY SHOWS

First mark the overall outline and lumen. Compare wall thickness in different directions, then add the boundaries of the tissue regions you can distinguish. Keep the cartilage gap in its observed position. If only a selected wall sector is requested, draw that sector rather than the whole tube.

3. KEEP THE DRAWING AT TISSUE LEVEL

Use a sharp pencil and single, continuous boundary lines. Leave out cilia, nuclei, chondrocytes and other individual-cell details. Do not shade or colour the plan. When labels are requested, use straight ruled lines ending on the correct region, with no crossing label lines.

Tracheal wall arrangement: Histology Guide, MH 136.
Drawing conventions: Cambridge Learner Guide (2015), pp. 20-21; archived copy.

Scope: Cambridge Biology 9700 syllabus, section 9.1, outcome 4, p. 29.

Plan diagram: bronchial wall

A bronchus inside the lung has discontinuous cartilage plates outside the smooth-muscle layer. Preserve their number, positions and shapes as seen, instead of drawing a memorised ring.

1. SEPARATE THE LINING, MUSCLE AND CARTILAGE

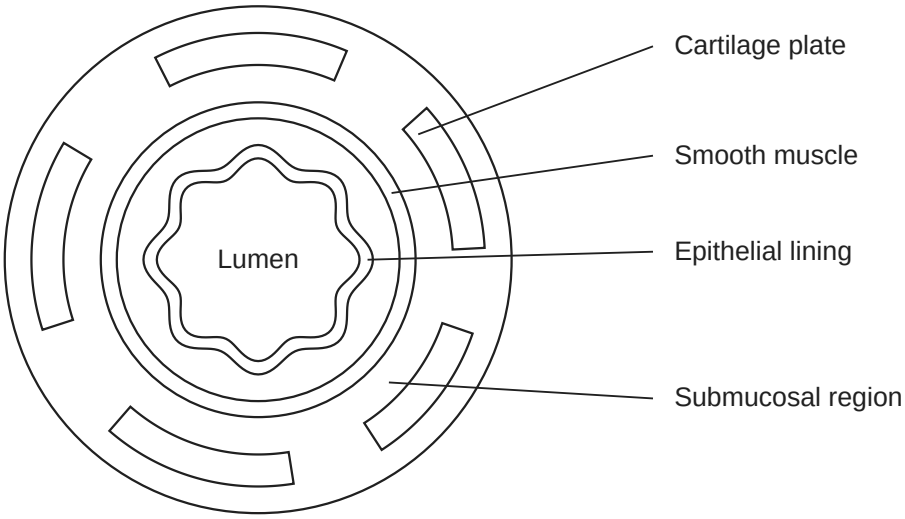

Teaching model, not to scale; glands and small vessels are omitted here.
Include additional tissue regions in your drawing if visible and requested.

2. CHECK THE RELATIVE POSITIONS

From the lumen outwards, recognise the epithelial lining and underlying connective tissue, the smooth-muscle layer, then the submucosal region and more external cartilage plates. The real wall is not a stack of perfectly even circles. Preserve folds and uneven thickness where you can see them.

3. FINAL CHECK: A PLAN, NOT A CELL DRAWING

Does the drawing match the requested region and fill the available space? Are the tissue proportions faithful to the specimen? Are boundaries clear, with no invented cells or shading? Add a descriptive title and any labels or scale information requested. Do not invent a numerical scale for a schematic.

Bronchial tissue layers and cartilage plates: Digital Histology, Secondary Bronchus 3.
Plan-drawing method: Cambridge Learner Guide (2015), pp. 20-21; archived copy.

Scope: Cambridge Biology 9700 syllabus, section 9.1, outcome 4, p. 29.