Start at the airway surface

Find the lumen, then inspect the cells along its edge. Identify tissues using visible shape, position and neighbouring structures, rather than using colour or function alone.

1. CILIATED EPITHELIUM AND GOBLET CELLS

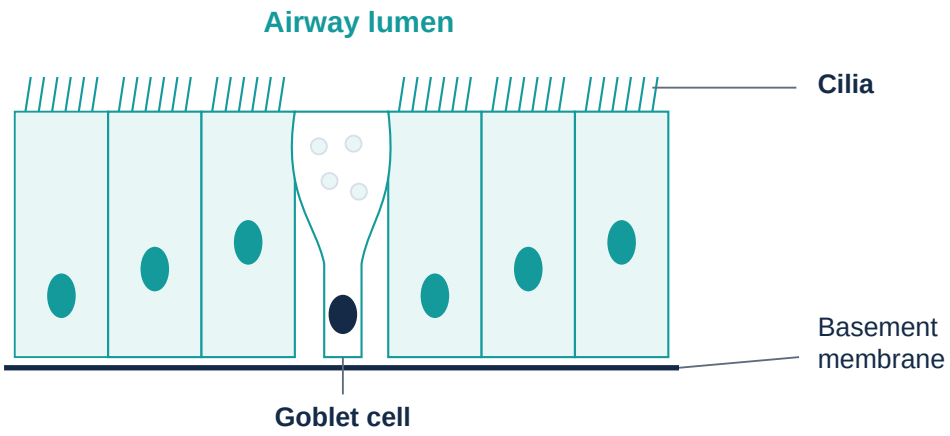

Simplified recognition sketch, not a photomicrograph. Basal cells are omitted. Real cell borders and cilia may be less distinct, and staining changes their appearance.

2. CILIATED EPITHELIUM: LOOK FOR A SURFACE FRINGE

Look for closely packed lining cells with fine projections facing the lumen. In the trachea, nuclei occur at different heights in pseudostratified epithelium; this does not mean it has many true layers. At low resolution, individual cilia may merge into a fuzzy border.

3. GOBLET CELL: LOOK FOR THE EXPANDED APEX

A goblet cell lies among the lining cells. Its mucus-containing upper region is expanded, often appearing pale in routine light microscopy, with the nucleus nearer the narrow base. In a TEM image, secretory granules occupy the apical cytoplasm. Goblet cells themselves are not ciliated.

Open a real trachea slide: Histology Guide, MH 136.
View a tracheal goblet-cell electron micrograph: Digital Histology, Unicellular 4.

Scope: Cambridge Biology 9700 syllabus, section 9.1, outcome 3, p. 29.

Inspect the deeper airway wall

Cartilage and smooth muscle are not the luminal epithelium. First locate them in the wall, then use the organisation of their cells and surrounding material to distinguish them.

1. CELL SHAPE PLUS TISSUE ORGANISATION

Hyaline cartilage

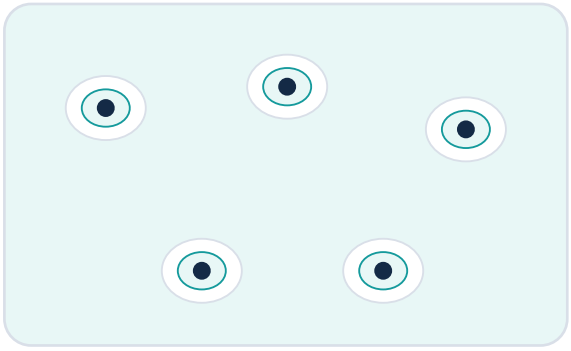

Cells in lacunae within matrix

Smooth muscle

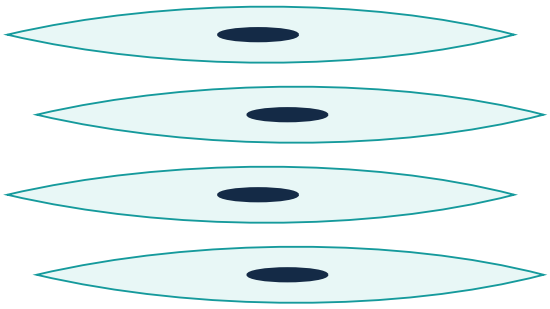

Tapered cells; elongated nuclei

Recognition sketches; muscle cells are shown lengthways. Not to scale.

2. CARTILAGE: MATRIX WITH CELLS IN LACUNAE

Hyaline cartilage contains rounded chondrocytes in small spaces called lacunae, sometimes in groups, within abundant extracellular matrix. In airways, look for supportive cartilage in the tracheal or bronchial wall. Do not call every pale patch cartilage: look for the characteristic cells and matrix.

3. SMOOTH MUSCLE: BUNDLES WITHOUT STRIATIONS

Longitudinal sections show closely packed, tapering cells with elongated central nuclei and no cross-striations. A transverse cut gives small round profiles; not every profile includes a nucleus. Use the bundle arrangement and wall position as well as cell shape. A single dark line is not enough evidence.

Cartilage matrix, chondrocytes and lacunae: OpenStax, section 4.3.
Smooth-muscle cell shape and nuclei: OpenStax, section 4.4.

Scope: Cambridge Biology 9700 syllabus, section 9.1, outcome 3, p. 29.

Separate air spaces from vessels

Alveolar squamous epithelium is very thin. Capillaries lie within the intervening septa, not in the alveolar air spaces. Trace the boundaries before naming a cell.

1. SQUAMOUS LINING BESIDE A CAPILLARY



Capillary lumen with red blood cells

Enlarged schematic of one wall region. Clear red-cell centres represent pallor, not nuclei. The cell layers and basement-membrane region between them are exaggerated.

2. SQUAMOUS EPITHELIUM: THIN CYTOPLASM

Look for a thin lining of an air space with occasional flattened nuclei. In ordinary light micrographs, the full outline of each alveolar cell can be hard to resolve. TEM reveals the thin cytoplasmic layers more clearly. An alveolar septum includes more than just one epithelial cell layer.

3. CAPILLARIES: A SMALL BLOOD-FILLED LUMEN

A narrow lumen in an alveolar wall, often containing a red blood cell, supports identification as a capillary. Its endothelial wall is thin. A red blood cell has no nucleus in mammals; a nearby nucleus may belong to endothelium or another septal cell, so follow the cell boundary.

Use two observations: for example, a narrow lumen within a thin septum plus a red blood cell. Check the scale bar and section angle; absence from one field is not proof that a tissue is absent from the organ.

Open a real lung slide: Histology Guide, MH 138; inspect alveoli and capillaries.
Compare the airway lining with the same method: Histology Guide, MH 136.

Scope: Cambridge Biology 9700 syllabus, section 9.1, outcome 3, p. 29.