Different walls, different roles

Follow the change from supported, mucus-clearing airways to thin gas exchange surfaces. This lesson maps where the six named tissues or cell types occur.

1. THE TISSUE-LOCATION MAP

Tissue / cell	Trachea	Bronchi	Bronchioles	Alveoli
Cartilage	C-shaped rings	Plates within lung	Absent	Absent
Ciliated epithelium	Present	Present	Present; reduces distally	Absent
Goblet cells	Numerous	Present	Few proximally; absent distally	Absent
Smooth muscle	Posterior wall	Around airway	Prominent in wall	No muscular wall
Squamous alveolar epithelium	Not the lining	Not the lining	Not the usual airway lining	Main exchange lining
Capillaries	Supply wall	Supply wall	Supply wall	Dense network in septa

2. READ THE PATTERN, NOT JUST YES OR NO

Cartilage supports larger airways; smooth muscle remains important after cartilage disappears. Ciliated cells extend into bronchioles, although their frequency falls towards the exchange region. Goblet cells decrease along the airway tree and are absent from normal distal bronchioles and alveoli.

The map simplifies a gradual transition. Alveolar walls have no continuous smooth-muscle coat; muscle around nearby alveolar ducts and entrances should not be confused with the thin exchange wall.

Airway epithelial transitions: University of Leeds, Conducting Portion.
Distal airways, alveolar cells and capillaries: Histology Guide, MH 138.

Scope: Cambridge Biology 9700 syllabus, section 9.1, outcome 2, p. 29.

Support outside; lining inside

Cartilage and smooth muscle lie in the airway wall. Ciliated epithelial cells and goblet cells belong to the lining facing the lumen, the space through which air moves.

1. COMPARE THREE AIRWAY WALLS

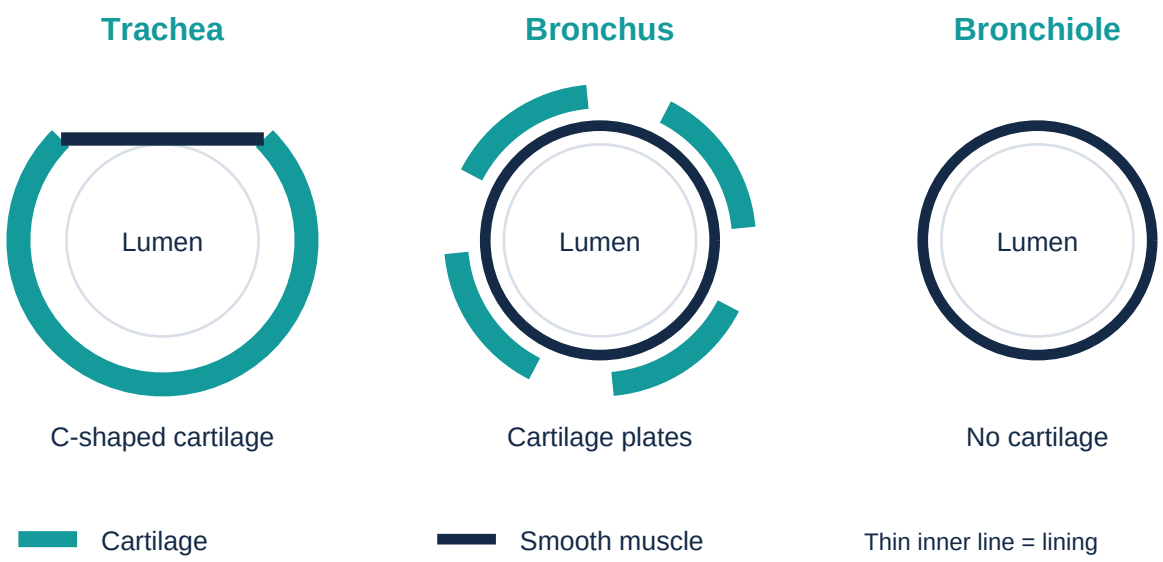

Simplified cross-sections; sizes and wall thicknesses are not to scale.

2. LOCATE THE MUSCLE PRECISELY

In the trachea, the trachealis muscle spans the posterior gap between the ends of each cartilage ring. Within the lung, bronchi have cartilage plates outside their smooth-muscle layer. Bronchioles lack cartilage but retain smooth muscle around the airway, enabling changes in its diameter.

3. LOCATE THE CLEANING CELLS

In the trachea and bronchi, goblet cells are interspersed among ciliated epithelial cells. Goblet cells release mucus onto the surface; cilia project into the lumen and move the mucus towards the throat. Cartilage is deeper in the wall, not part of this epithelial surface.

Tracheal cartilage, muscle and lining: Histology Guide, MH 136.
Bronchial wall arrangement: Digital Histology, Secondary Bronchus 3.

Scope: Cambridge Biology 9700 syllabus, section 9.1, outcome 2, p. 29.

A thin lining beside capillaries

Most alveolar surface area is covered by flattened type I cells: simple squamous epithelium. Capillaries run within the thin septa, the walls separating neighbouring alveoli.

1. TWO CELL LAYERS SEPARATE AIR FROM BLOOD

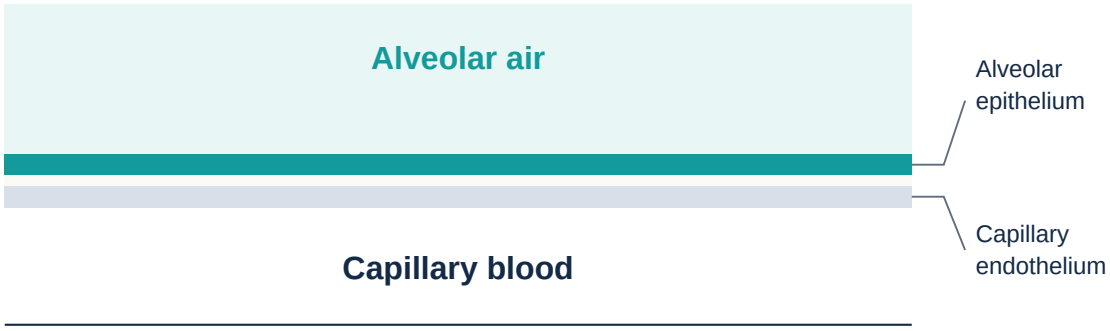

A thin basement-membrane layer lies between the two cell layers.

Flattened, enlarged schematic; not to scale. The complete capillary network extends through the surrounding alveolar septa, not through the air spaces.

2. DO NOT PUT AIRWAY TISSUES IN THE ALVEOLAR LINING

Alveoli have no cartilage, goblet cells or ciliated lining. A thick mucus-covered, ciliated layer would not provide the short diffusion distance of the thin squamous surface. Capillary endothelium is also thin, but it lines the blood vessel; it is not the alveolar epithelium.

3. SQUAMOUS DOES NOT MEAN EVERY CELL IS FLAT

Type I cells cover most of the exchange surface. Alveoli also contain type II cells, which are more cuboidal and produce surfactant; they are not goblet cells. For this lesson, recognise the dominant squamous lining and the closely associated capillary network.

Capillaries also nourish airway walls. Their presence alone does not identify an alveolus; look for their close association with very thin air-space walls.

Type I and II cells and the respiratory membrane: OpenStax, section 22.1.
Alveolar septa and capillaries: Histology Guide, MH 138.

Scope: Cambridge Biology 9700 syllabus, section 9.1, outcome 2, p. 29.