Blood cells: start with the nucleus

Use several visible clues together: cell outline, nucleus shape, amount of cytoplasm and relative size. This lesson focuses on four cell types in normal mammalian blood.

1. RED BLOOD CELL: A BICONCAVE DISC

Face view

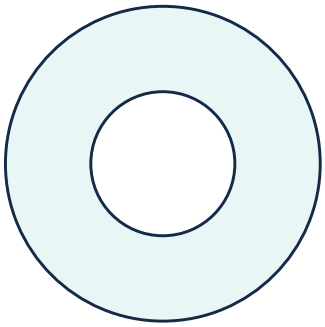

Paler centre in a stained smear

Edge-on profile

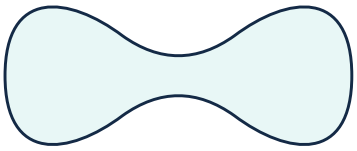

Thin centre; thicker rim

Original schematics, not micrographs or a shared size scale. The pale centre represents a thinner region, not a hole or a nucleus. An intact red blood cell is not a ring.

2. WHAT TO RECOGNISE

A mature mammalian red blood cell has no nucleus and is usually smaller than the white blood cells nearby. In a well-spread stained smear, many appear as similar round discs with central pallor. Overlap, distortion and viewing angle can change the outline.

3. STRUCTURE GIVES USEFUL CONTEXT

Haemoglobin in the cytoplasm carries oxygen. Biconcavity gives a high surface-area-to-volume ratio and a short diffusion path. Flexibility allows passage through narrow capillaries. Mature mammalian red blood cells lack a nucleus and most organelles.

Do not identify a cell from pink or purple alone: colour depends on the stain. A tiny irregular fragment may be a platelet rather than one of the four cell types studied here.

Red-cell shape, smear and scanning EM examples: University of Leeds, Red Blood cells.
Comparison with surrounding blood cells: Histology Guide, Blood Cells.

Scope: Cambridge Biology 9700 syllabus, section 8.1, outcome 5, p. 27.

Three white-cell patterns

Compare nucleus shape and the amount of cytoplasm first. Size is supporting evidence: blood-cell sizes overlap, and apparent size depends on magnification.

1. NEUTROPHIL

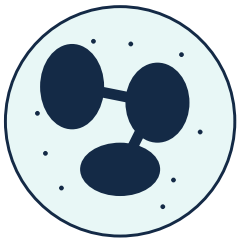

One nucleus divided into linked lobes; fine granules in the cytoplasm. Do not call the lobes separate nuclei. Neutrophils are phagocytes that can engulf microbes.

2. LYMPHOCYTE



A typical small lymphocyte has a large, roughly round nucleus and only a narrow rim of cytoplasm. Some are larger. B and T lymphocytes cannot reliably be distinguished by an ordinary blood smear.

3. MONOCYTE



Usually a large cell with abundant cytoplasm and an indented, kidney-shaped or folded nucleus. It is not divided into distinct linked lobes. Monocytes can enter tissues and differentiate into macrophages.

Original recognition schematics; colour separates nucleus from cytoplasm and does not reproduce a particular stain. Cells are enlarged separately, not drawn to a common scale.

White-cell recognition and context: University of Leeds, White Blood cells.
Real smear examples and linked electron micrographs: Histology Guide, Blood Cells.

Scope: Cambridge Biology 9700 syllabus, section 8.1, outcome 5, p. 27.

Observe, identify, draw

A blood-cell drawing includes the visible cell and nuclear outlines. Unlike a tissue plan diagram, it shows cellular detail - but only the detail supported by the specimen.

1. EXAMPLE: LABEL A SMALL LYMPHOCYTE

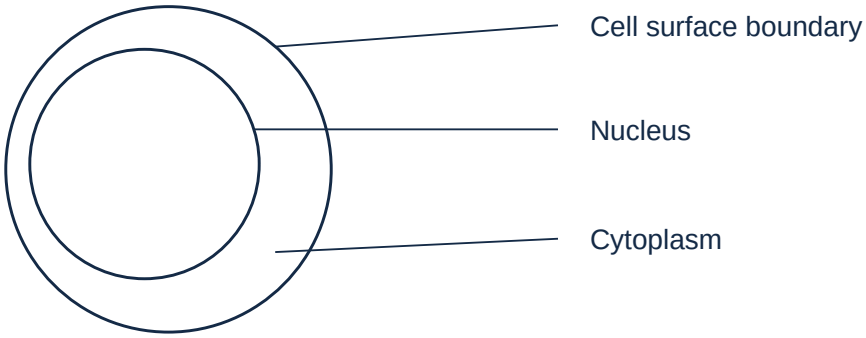

Original outline example, not a drawing from a supplied microscope field. Keep the nucleus-to-cell size ratio accurate. Leave cytoplasm unshaded; label lines do not cross.

2. MAKE AN EVIDENCE-BASED BIOLOGICAL DRAWING

Choose a clear, non-overlapping cell. Draw it large with single, continuous pencil lines. Preserve the shape and proportions of the nucleus, cytoplasm and cell boundary. Add visible granules when required; avoid shading and invented organelles. Give the cell name and an appropriate title.

3. TRANSFER THE CLUES TO ELECTRON MICROGRAPHS

A TEM section shows internal structure, so nuclear shape and cytoplasmic granules are useful. In a neutrophil, nuclear lobes may appear separate if their connections lie outside the section. SEM shows surface shape, such as red-cell biconcavity; it does not directly show an internal nucleus.

Use a supplied scale bar or magnification, never these schematics, to estimate actual size. If a section misses a nucleus, do not conclude from that fact alone that the cell is a red blood cell.

TEM nuclear lobes and granules: Histology Guide, EM 331 Neutrophils.
Microscope comparisons: Histology Guide, Blood Cells.

Scope: Cambridge Biology 9700 syllabus, section 8.1, outcome 5, p. 27.