Recognising blood vessels

Identify a vessel using several visible features together. Start with the lumen, then compare wall thickness and the arrangement of its tissues.

1. TRANSVERSE SECTION: CUT ACROSS THE VESSEL

ARTERY

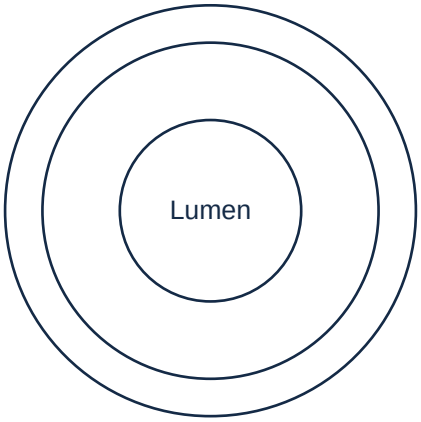

Thick wall relative to lumen

VEIN

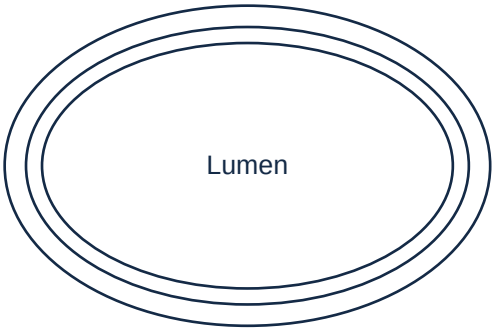

Thinner wall; relatively wide lumen

Original, simplified plan schematics; not microscope observations or a shared size scale. Internal lines mark broad tissue boundaries, not individual cells.

2. ARTERY: LOOK FOR A SUBSTANTIAL MIDDLE LAYER

A muscular artery has a prominent smooth-muscle layer between the inner lining and outer connective tissue. Elastic tissue may appear as wavy lines. The lumen often retains a rounded profile. Compare the wall with the lumen, not just the total diameter.

3. VEIN: USE THE WALL, NOT SHAPE ALONE

A comparable vein usually has a thinner muscular layer and a larger lumen. Its thin wall may collapse, producing an irregular outline. A visible valve supports identification as a vein, but a vein section does not have to contain a valve.

All three vessel types have an endothelial lining. Shape and stain colour alone do not identify a vessel; section angle and preparation can alter its appearance.

Real microscope examples: Columbia University, Blood Vessels.

Scope: Cambridge Biology 9700 syllabus, section 8.1, outcome 3, p. 27.

Recognise a capillary at high power

Capillaries are much smaller than the arteries and veins on page 1. Their defining feature is a very thin endothelial wall, without a surrounding continuous smooth-muscle coat.

1. ENLARGED CAPILLARY: TRANSVERSE SECTION

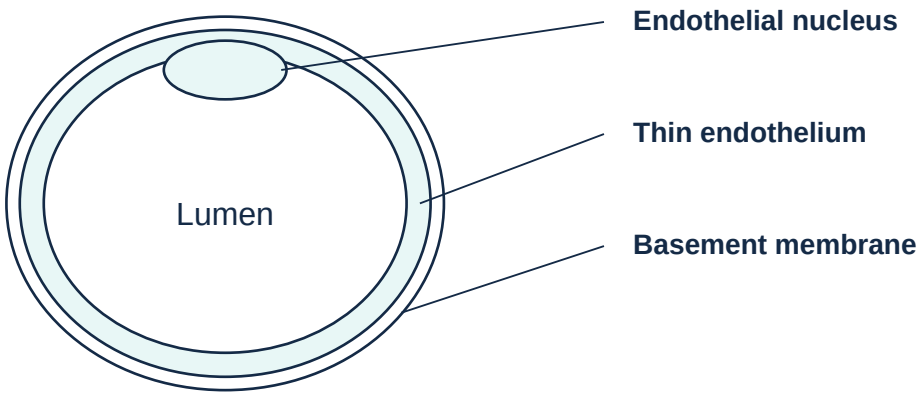

Original schematic of a continuous capillary, not an electron micrograph. Its nucleus bulges towards the lumen; most of the cell is much thinner. Boundaries are enlarged for clarity.

2. LIGHT MICROGRAPH: FIND THE TINY CHANNEL

Look for a narrow lumen among tissue cells, sometimes containing a single red blood cell across its width. A flattened endothelial nucleus may lie at its edge. Do not mistake a tissue gap for a vessel: trace a genuine lining.

3. ELECTRON MICROGRAPH: TRACE THE THIN WALL

At higher resolution, follow the thin endothelial cytoplasm around the lumen and the supporting basement membrane outside it. A nucleus may be prominent, but the section may miss it. There are no thick muscular and connective-tissue layers like those of an artery.

One cell thick describes the wall, not the number of cells along the whole vessel. Use the scale bar: a highly enlarged capillary can look bigger on the page than an artery.

Real light and electron micrographs: University of Leeds, Capillaries.

Scope: Cambridge Biology 9700 syllabus, section 8.1, outcome 3, p. 27.

From section to plan diagram

A plan diagram shows the positions and proportions of tissue regions. Draw the specimen you can actually see, rather than replacing it with an idealised textbook vessel.

1. LONGITUDINAL SECTION: CUT ALONG THE VESSEL



Simplified open-ended plan schematics. No individual cells are drawn. Compare with TS on page 1: LS gives long wall bands; an oblique cut can produce an elongated profile.

2. OBSERVE FIRST, THEN SET THE PROPORTIONS

At low power, locate the whole vessel and establish TS or LS. Compare its outside dimensions, lumen and tissue-layer widths. Make a large drawing in sharp pencil, keeping those proportions; represent visible boundaries with single, clear lines.

3. KEEP IT A PLAN, NOT A CELL DRAWING

Do not add individual cells, nuclei, shading or decorative colour. Label the lumen and the tissue regions that are distinguishable. Use straight, non-crossing label lines that end precisely on the relevant boundary or region. Add a title and section orientation.

If requested, include a scale bar or calculate magnification using image size divided by actual size, in the same units. Never invent a scale from these schematics. To identify an unknown, report visible evidence before naming the vessel.

Real microscope examples: Columbia University, Blood Vessels.

Scope: Cambridge Biology 9700 syllabus, section 8.1, outcome 3, p. 27.